

# Biomaterials for bone regeneration in oral surgery:

## A multicenter study to evaluate the clinical application of “R.T.R.” (β-Tricalcium Phosphate)

**Paolo Brunamonti Binello:** Consultant Professor, University of Genoa

**Giuseppe Galvagna:** Private practice, Catania, Italy

**Massimo Galli:** Private practice, Pistoia, Italy

**Mauro Labanca:** Consultant Professor in Oral Surgery and Anatomy, Milan, Italy

In Literature there isn't any conflicting data about the clinical results obtained in Oral Surgery for bone regeneration using Biomaterials of either animal or synthetic origin.<sup>(1)</sup>

What is the most important, however, is the creation of a microenvironment suitable for the proliferation and differentiation of hard tissues, such as to successfully promote the regeneration of new bone at the implant-prosthetic purposes.<sup>(1-2)</sup>

For this reason, therefore, the Authors always prefer the use of synthetic materials with reduced risk of inflammation and complete absence of potential cross infections.<sup>(1)</sup>

The Goal of this study is, therefore, to illustrate - through a case series - short term results of a multicenter research on bone regeneration in Oral Surgery by using an heterologous filling material that consists of Beta-Tricalcium Phosphate, called R.T.R.

## Introduction

International Literature about bone regeneration in implant dentistry describes many different available surgical techniques and the following are the principal:

- Guided Bone Regeneration (G.B.R.)
- Bone Grafting
- Osteogenic Distractions

Each of the above mentioned methods, while presenting different and precise application limits (mostly related to the type of defect and

the surgical technique), turned out to be predictable if done correctly.<sup>(3)</sup>

The Literature data, then, show how - osteogenic distractions aside - the use of a biomaterial (regardless of its origin, whether animal or synthetic) is helpful if not indispensable to the attainment of an adequate clinical outcome.<sup>(4)</sup>

Finally, the use of semi-permeable barriers - whether or not absorbable membranes - rather than metal grids, in order to maintain a suitable

space, has proved indispensable in G.B.R., while it is still extremely discussed in other regenerative techniques.<sup>(5)</sup>

In fact, when we speak about Biomaterials in Regenerative Oral Surgery it is appropriate to make a distinction between the following elements:

- Semi-permeable membranes: they allow the stabilization of cloth and the selection of cell lines that will colonize the bone defect (space maintainer = maintenance of biological space).
- Filling material: Support the membrane and act as a "scaffold" for the migration, growth and differentiation of pre-osteoblasts into osteoblasts.

To contribute to the regeneration process, here are the following basic mechanisms of Osteo-

genesis, understood as a budding center of deputies to the new bone genesis:

- Osteoinduction: stimulation of the differentiation of mesenchymal cells in preosteoblasts.
- Osteoconduction: biological scaffold as a support to new cells in the differentiation process.

It is deduced that the new bone tissue formation occurs if the following organic conditions exist:

- Availability of mesenchymal cells capable of differentiating following the osteoinductive input
- Presence of osteoinductive input ("Osteoinductive Boost"), which initiates the differentiation of mesenchymal preosteoblasts in osteoblasts
- Existence of an osteoconductive environment that promotes the colonization and proliferation of graft.

## R.T.R. (beta-tricalcium phosphate)

Except for autologous bone, on the fundamental concepts of Osteogenesis, remains today still open the debate as to which type of currently available bone grafting material is the best.<sup>(6)</sup>

Given that, the Authors have carried out a multi-center research about clinical application of a synthetic filler (already known for years on the market) based on Beta-Tricalcium Phosphate for bone regenerative purposes, called "R.T.R. (Resorbable Tissue Replacement)".<sup>(6)</sup>

The  $\text{Ca}_3(\text{PO}_4)_2$  powder (treated with naphthalene and subsequently compacted by sintering) form the Beta-tricalcium phosphate, with macropores of a diameter between 100 and 300 microns ideal, that is, for the Osteoconduction.<sup>(6)</sup>

This heterologous biomaterial, once placed, is completely absorbed in 6 or 9 months, and replaced by new bone.<sup>(6-7)</sup>

Recent studies on large crestal defects show a significant increase in the regeneration with Beta-Tricalcium Phosphate already after 2 weeks compared to the other control sites, thereby proving the effectiveness of this filling material.<sup>(7)</sup>

During resorption, in addition, Beta-Tricalcium Phosphate provides with Ca ions and phosphate

into the site of regeneration: this creates an ideal ionic concentration with an alkaline pH, which stimulates the activation of alkaline phosphatase enzyme, which is essential to the ossification process.<sup>(6-8)</sup>

Then, all resources of this study and the attention of the authors are focused on the use of Beta-Tricalcium Phosphate called "R.T.R." basically because this synthetic biomaterial would possess - as a prerequisite - all the features that a generic filling material should have -with the exception of Osteoinduction.<sup>(6-7-8)</sup>

These characteristics may be summarized as follows:

- High biocompatibility and minimum autoimmune response
- Bio-inert (absence of local inflammatory reaction)
- Ideal time of resorption for the type of bone defect
- Total reabsorption
- Excellent osteoconductivity
- Good packaging
- High handling during surgery
- Absolutely no risk of cross-infection transmission

In particular, since “R.T.R.” is completely resorbable over a period of time, reasonably useful for important bone defects resolution, the authors think “R.T.R.” is particularly appropriate for all regenerations conducted for the purpose of

implant-prosthetic rehabilitation, in contrast with many other filling materials that do not resorb completely - and allow only a repair instead of a healing of the bone defect.<sup>(8-9)</sup>

## Materials and methods

This multicenter Study provides for the regeneration of bone tissue with Beta-tricalcium phosphate “R.T.R.” in patients with a residual bone defect of the maxillary and with implant-prosthetic rehabilitation purposes.

The selection of patients is randomized. However, in order to standardize the number of cases, this random selection requires that patients have the following basic requirements:

- Aged between 20 and 60 years
- Either male or female
- Non-smokers
- In good general health
- Having at least a residual crestal bone defect

Regarding the type of defect, it is deliberately excluded to standardize the same, in terms of morphology and etiopathogenesis, in order to verify the regenerative effectiveness of “R.T.R.” in different conditions of bone atrophy (and, therefore, of different “regenerative thrusts”).

It is, therefore, decided to treat the following clinical situations:

- Post-extractive sites
- Bone regeneration around implants placed in areas with deficiencies in bone or post-extraction
- Overall G.B.R. (sinus lift or major bone defects)

## Case series

The Authors, from 4 different cities and from different working situations (private practice, hospital and private clinic) have treated 12 patients with the following bone defects:

- N 3 peri-implant defects
- N 2 sinus floor lifts
- N 4 post extractive sockets
- N 3 bone defects of various types

In all cases, the patients were subjected to antibiotic therapy with 200 mg / day of Doxycycline (in 2 doses daily beginning the day before surgery up to 8 days after the intervention), to daily repeated rinses with chlorhexidine and therapy with FANS as needed (Ibuprofen 800 mg / day in single-dose).

## Case Report no.1

The first is a case report of a 54-year-old male patient, in good health general conditions, with a mandibular residual cyst in area 46. (*Fig. 1-2-3*) In accordance with the patient, we opted for an intervention of Partsh II, filling the remaining cavity with R.T.R. granules without using semi-

permeable membranes. (*Fig. 4-5-6-7-8*)

About 6 months after the first surgery, the next step will involve the placement of one implant. The local objective examination and routine radiographic examination showed a good healing short-term. (*Fig. 9-10-11*)

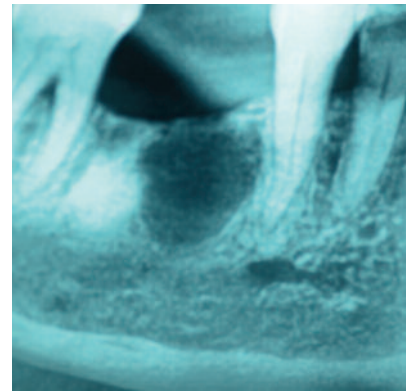
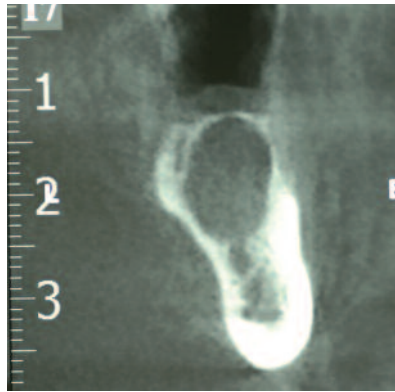
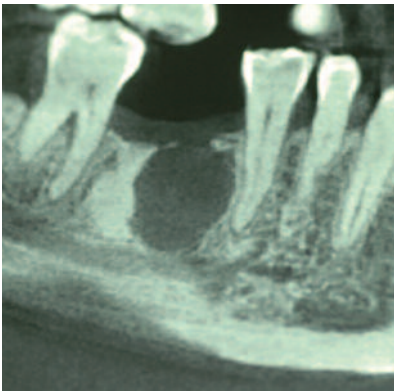


Fig. 1-2-3: mandibular residual cyst in area 46.

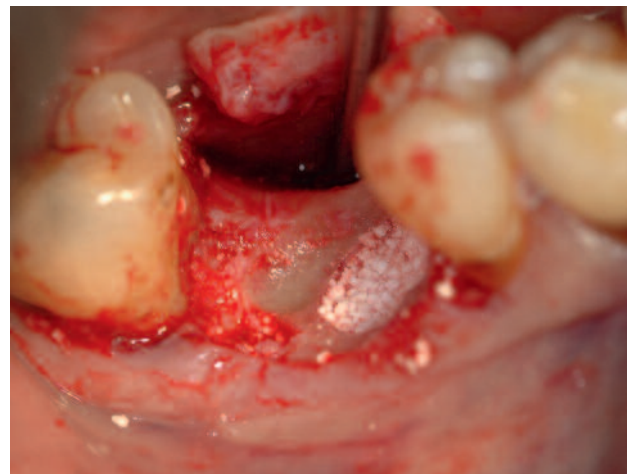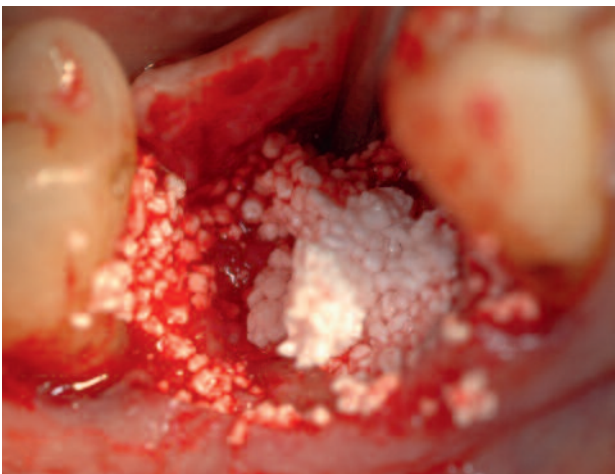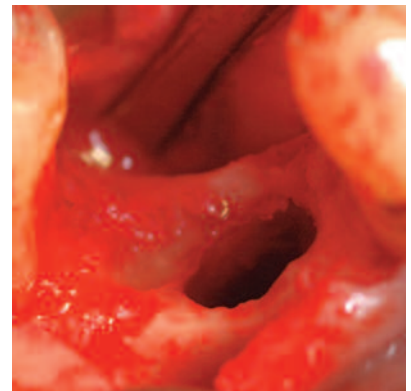
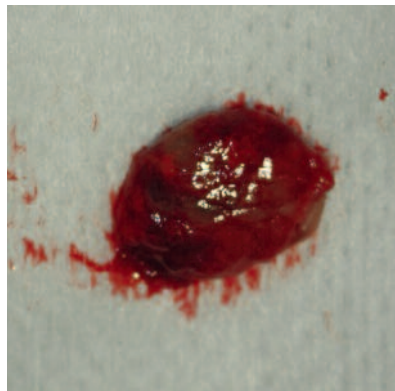
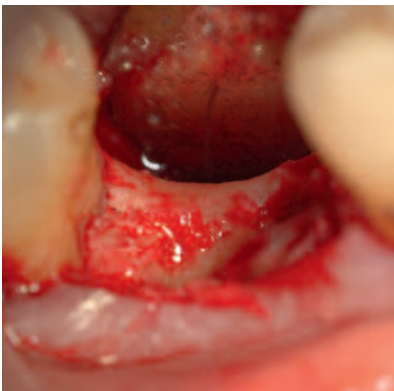


Fig. 4-5-6-7-8: Intervention of Partsh II and filling the remaining cavity with R.T.R. without using semi-permeable membranes.

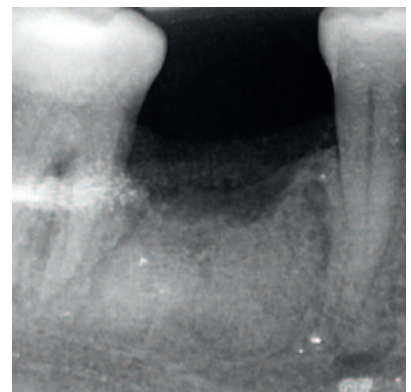
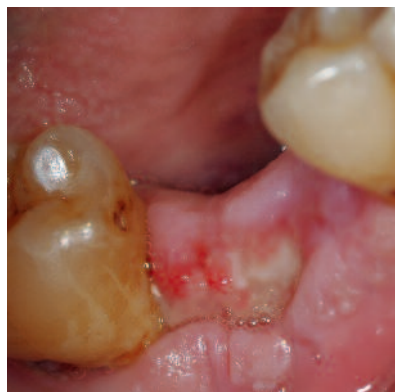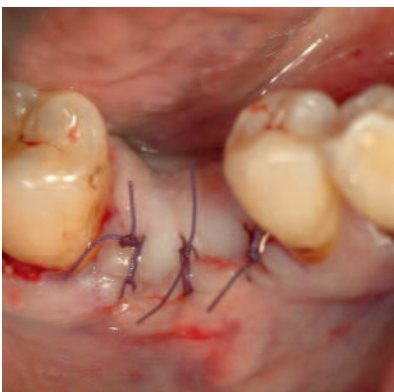


Fig. 9-10-11: The local objective examination and routine radiographic examination showed a good healing short-term.

## Case Report no.2

The second case report is a 45-year-old female patient, in good general health conditions with edentulous in area 25-26 and progressive atrophy of the corresponding alveolar process. (Fig. 12-13)

In accordance with the patient, by full-thickness mucosal flap in the area 25-26, we opted for a transcrestal sinus floor lift with a R.T.R. graft and simultaneous placement of two fixtures. In this case R.T.R. has been used also as a filling material around implants contextually.

For this case the syringe form of R.T.R. has been chosen.

The fixtures had a good primary stability, equal to about 60 newtons. (Fig. 14-15)

The subsequent exposition of the implants and the beginning of the prosthetic phase will be managed about 6 months after sinus lift procedure.

The good health of the superficial soft tissues and surveys Rx screening show the excellent health of deep tissues in short term. (Fig. 16-17)

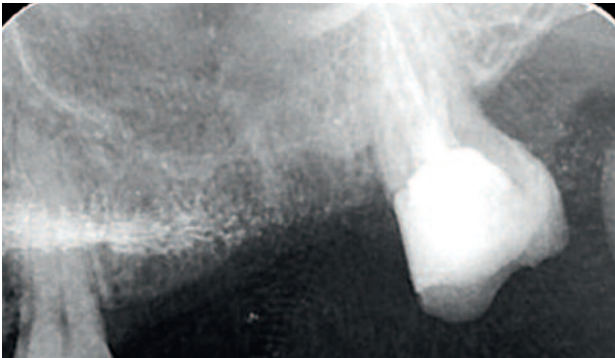


Fig. 12-13: edentulism in area 25, 26 with partial atrophy of the alveolar process residue.

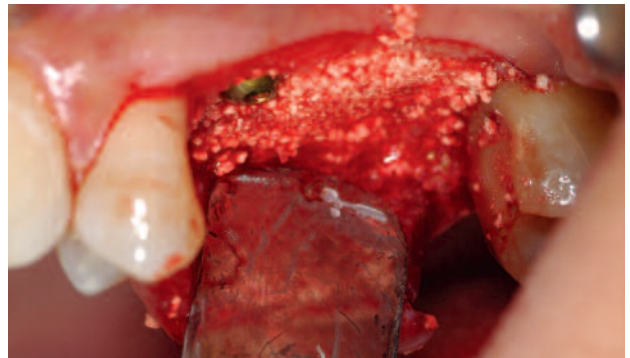
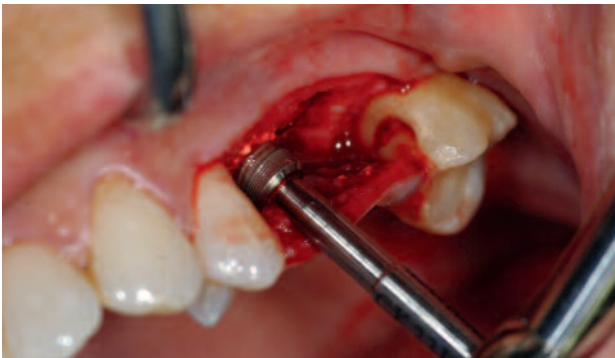
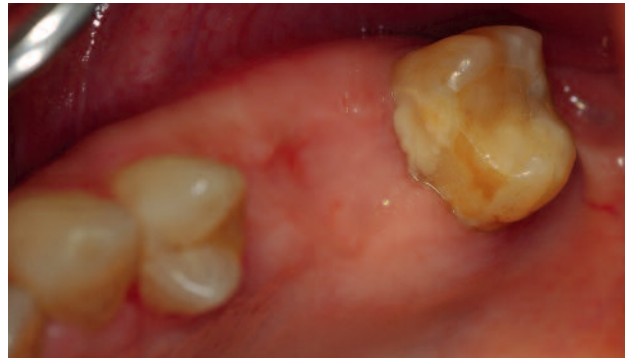
Fig. 14-15: Full-thickness mucosal flap in the area 25-26 and transcrestal sinus floor lift with a R.T.R. graft to a simultaneous placement of two fixtures. R.T.R. has been used also as a filler around implants.

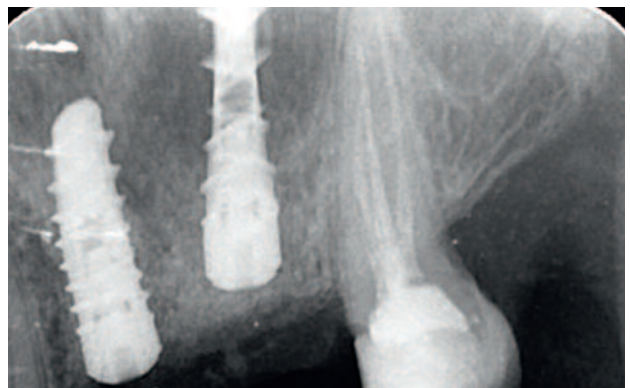
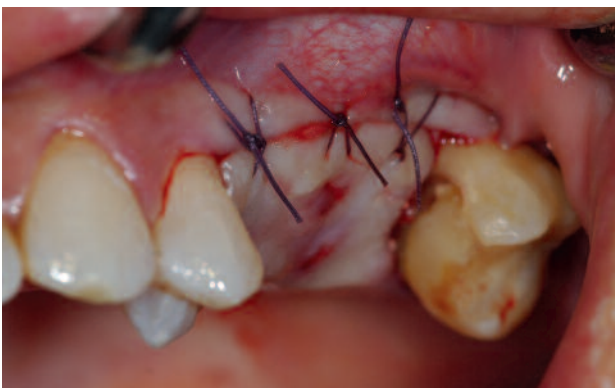
Fig. 16-17: The good health of the superficial soft tissues and surveys Rx screening show the excellent health of deep tissues in short term.

# Case Report no.3

The third case report involves a 52-year-old female patient, in good general health conditions, who has been subject to avulsion of the elements 16 and 17, because they were irreparably compromised and extremely symptomatic. (Fig. 18-19-20)

In area 16, for regenerative purposes, has been

executed a graft of R.T.R., presented in a cone with collagen. (Fig. 21-22-23-24-25)

About 6 months following R.T.R. graft will be positioned an implant.

Also in this clinical case as in the others the local objective examination and the Rx screening showed an excellent recovery in the short term.

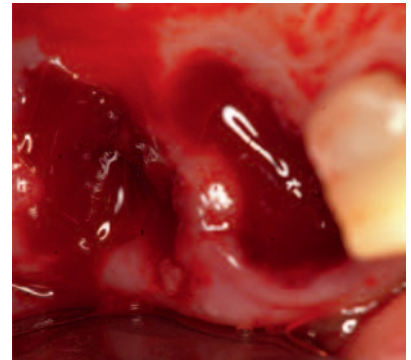
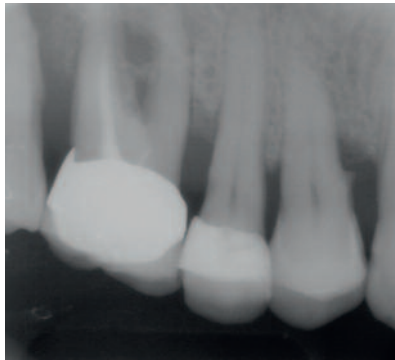
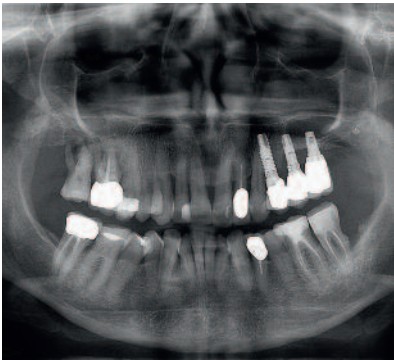


Fig. 18-19-20: avulsion of the elements 16 and 17 due to a severe periodontal defect.

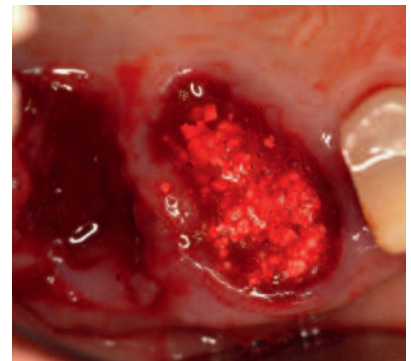
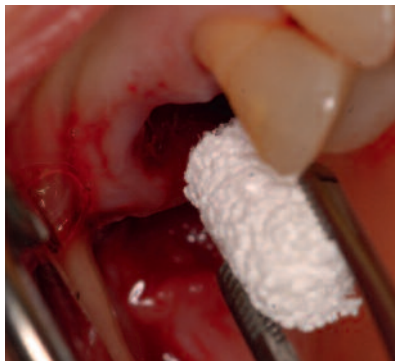
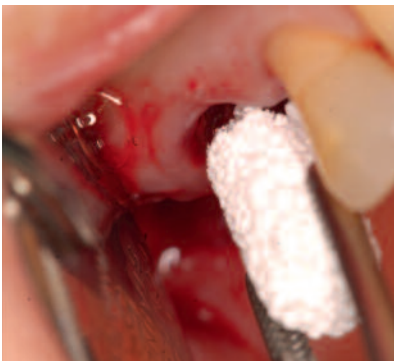
Fig. 21-22-23: In area 16, in regenerative purposes, has been executed a graft of R.T.R.

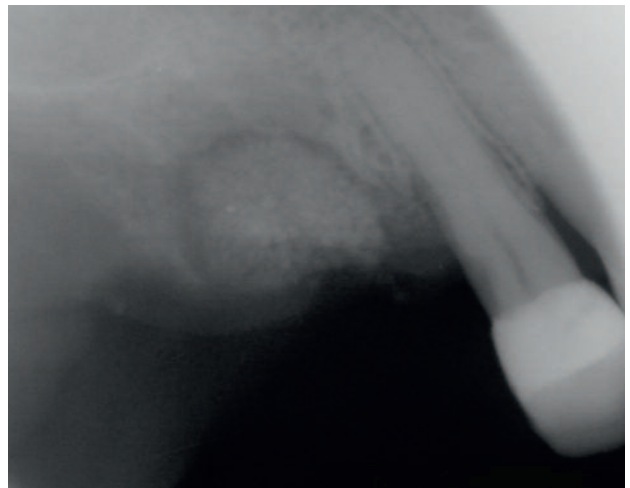
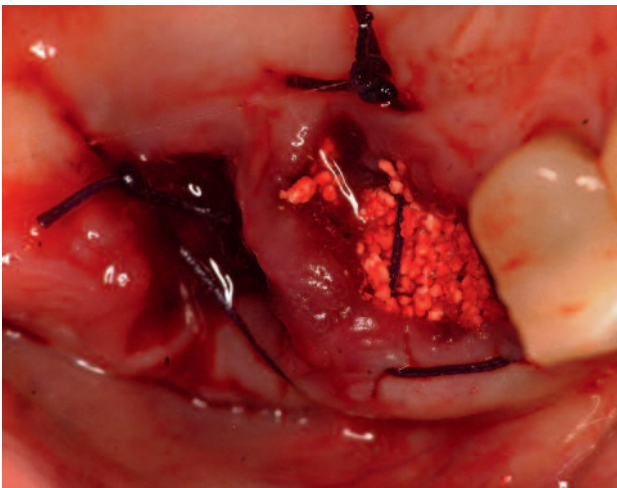


Fig. 24-25: immediate post op clinical and radiological situation.

## Discussion

The post-surgical follow-up in the short term (which provides an objective local examination and Rx control after 8 days and also in following weeks after the first surgical step) showed that in all cases treated were found the following items:

- Good immediate healing of superficial soft tissues
- Excellent radiographic condition of deep tissues
- Absence of autoimmune reactions
- Absence of local reactive inflammation
- Absence of excessive bleeding

The authors also confirm that R.T.R. material, besides having a packaging extremely functional, has expressed high qualities of practicality and manageability during the surgical procedure, in its mode of use, application and compaction (in all the forms of packaging).

The on-going research, currently in the initial phase, involves a series of stages, in which will also be performed (if and where possible) the implant-prosthetic rehabilitation of bone defects treated and, if possible, a histological evaluation suitable to document the degree of absorption and regeneration.<sup>(10-11)</sup>

## Conclusion

The interesting initial and partial results obtained to date are encouraging for the authors to continue the study in progress.

The goal remains to propose a predictable therapeutic solution, though alternative and not a replacement of the other existing and fully described in the Literature.<sup>(12-13-14-15-16)</sup>



### Authors (left to right)

**Mauro Labanca:** From 2001 to 2005: Creator and Director of the very first Italian course “Anatomical surgery with Cadaver lab”. From 2006 up to date: Director of the course of “Anatomical surgery with Cadaver lab” at the Institute of Anatomy at the University of Wien, Austria. 2006: Creator and Director of the first Master of Marketing and Communications in Medicine and Private Dentistry at IULM University (Libera Università di Lingue e Comunicazione) in Milan, Italy. From 2007 up to date: International Consultant in Dentistry for MEDACorp, Leerink Swann LLC Boston, MA, USA. From 2007 up to date: Consultant Professor of Oral Surgery in the department of Dentistry at “Vita e Salute University” - S. Raffaele Hospital – Milan, Italy. From 2008 up to date: Consultant Professor of Anatomy in the Department of Medicine at the University of Brescia, Italy. 2009: Co-Founder and vice President of the Italian Society for the study of Oro-Facial Pain (SISDO). 2011: Founder and President of the “Labanca Open Academy” (LOA) devoted to the improvement of all aspects of Dentistry. Created to have an open network among all participants of his courses. From 2012: Visiting professor at the Periodontology Department of the “Universitat Internacional de Catalunya”, Barcellona, Spain.

**Paolo Brunamonti Binello:** Consultant Professor, University of Genoa. Executive Doctor “Galliera Hospital”, Genoa, Italy

**Giuseppe Galvagna:** Private practitioner, Catania, Italy

**Massimo Galli:** Oral surgeon and private practitioner, Pistoia, Italy

## References

---

01. Labanca M, Leonida A, Rodella FL. Natural or synthetic biomaterials in Dentistry: Science and ethic as criteria for their use. *Implantologia* 2008; 1:9-23
02. Nociti FH Jr, Machado MA, Stefani CM, Sallum EA, Sallum AW. Absorbable versus nonabsorbable membranes and bone grafts in the treatment of ligature-induced per-implants defects in dogs. Part I. A clinical investigation. *Clinical Oral Implants Research* 2001;2:115-120.
03. Hardwick R, Scantlebury T, Sanchez R, Whitley N, Ambruster J. Membrane design criteria for guided bone regeneration of the alveolar ridge. In: Buser D, Dahlin C, Schenk RK, eds. *Guided bone regeneration in implant dentistry*. Chicago, IL: Quintessence. 1st edition, 1994;101- 136.
04. Dahlin C, Linde A, Gottlow J, Nyman S. Healing of bone defects by guided tissue regeneration. *Plastic and Reconstructive Surgery* 1988;81:672-676.
05. Hockers T, Abensur D, Valentini P, Legrand R, Hammerle CH. The combined use of bioresorbable membranes and xenografts or autografts in the treatment of bone defects around implants. A study in beagle dogs. *Clinical Oral Implants Research* 1999;6:487-498.
06. Coetzee AS. Regeneration of bone in the presence of calcium sulfate. *Arch Otolaryngol* 1980;106:405-409.
07. Irrigary J. A study of atomic elements diffusion in coral after implantation in vivo. *Publication de Biomat Bordeaux, France* 1987:241-248.
08. Guillemin G. The use of coral as bone graft substitute. *Journal of Biomedical Materials Research* 1987;21:557-567.
09. Gielkens PF, Bos RR, Raghoobar GM, Stegenga B. Is there evidence that barrier membranes prevent bone resorption in autologous bone graft during the healing period? A systematic review. *Int J Oral Maxillofac Implants* 2007;22(3):390-398.
10. Raymond AY, Sotirios V. Comparative evaluation of decalcified and non-decalcified freeze-dried bone allograft in Rhesus monkeys. I. Histologic findings. *Journal of Periodontology* 2005 Jan;76(1):57-65.
11. Sommerland S, Mackenzie D, Johansson C, Atwell R. Guided bone augmentation around a titanium bone-anchored hearing aid implant in canine calvarium: an initial comparison of two barrier membranes. *Clin Implant Dent Relat Res* 2007;9(1):22-33.
12. Maeda H, Kasuga T. Control of silicon species released from poly(lactic acid)-polydimethylsiloxane hybrid membranes. *J Biomed Mater Res A* 2007; [Epub ahead of print].
13. Mattout P, Mattout C. Conditions for success in guided bone regeneration: retrospective study on 376 implant sites. *Journal of Periodontology* 2000;12:1904-1909.
14. Chou AM, Sae-Lim V, Huttmacher DW, Lim TM.: Tissue engineering of a periodontal ligament-alveolar bone graft construct. *Int J Oral Maxillofac Implants* 2006;21(4):526-534.
15. Kohal RJ, Hurzeler MB. Bioresorbable barrier membranes for guided bone regeneration around dental implants. *Schweiz Monatsschr Zahnmed.* 2002;12:1222-1229.
16. Hartman GA, Arnold R.M, Mills MP, Cochran DL, Melloing JT. Clinical and histologic evaluation of inorganic bovine bone collagen with or without a collagen barrier. *International Journal Periodontics Restorative Dentistry* 2004;2:127-135.