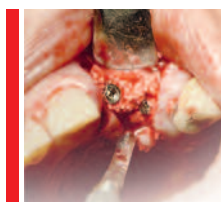

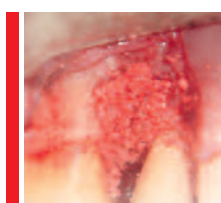
# Content



## Use of $\beta$ -tricalcium phosphate for bone regeneration in oral surgery

Giuseppe Galvagna, Paolo Brunamonti Binello,  
Massimo Galli and Mauro Labanca

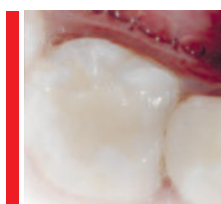
04



## Alloplastic Grafts - Beta-tricalcium phosphate

Mario Ernesto García-Briseño

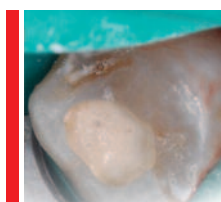14



## Biodentine™ - Pulpotomy on primary molars

Luc Martens and Rita Cauwels

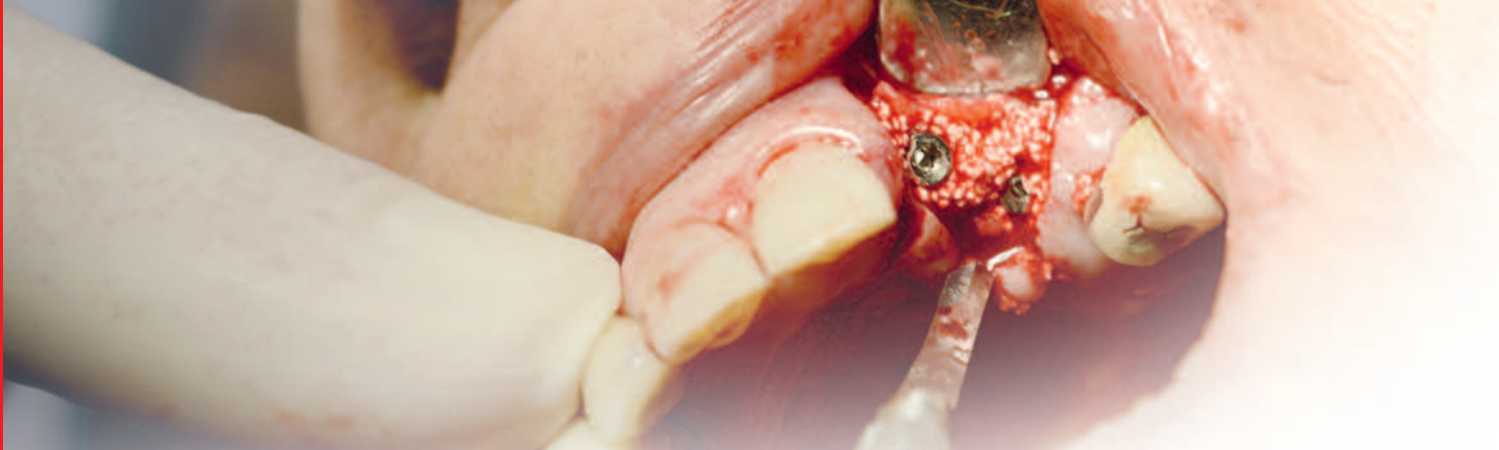21



## Biodentine™ - Pulp capping

Luc Martens and Rita Cauwels

26



# Use of $\beta$ -tricalcium phosphate for bone regeneration in oral surgery

## A multicenter study to evaluate the clinical applications of R.T.R. (Resorbable Tissue Replacement)

Giuseppe Galvagna: Private practice, Catania, Italy

Paolo Brunamonti Binello: Consultant Professor, University of Genoa

Massimo Galli: Private practice, Pistoia, Italy

Mauro Labanca: Consultant Professor in Oral Surgery and Anatomy, Milan, Italy

In prosthetic implant rehabilitation, loss of bone volume in atrophic maxillae is one of the major problems faced by surgeons in their clinical practice. In the presence of horizontal and vertical bone defects, atrophic ridges need to be restored to make them suitable for implant placement and for restoration of masticatory and aesthetical functions.

For this reason, in recent years the term “GBR” has been closely associated with the concept of prosthetically guided implantology.

The purpose of this study is to demonstrate the osteoconductive properties of synthetic biomaterials, particularly  $\beta$ -tricalcium phosphate or R.T.R., and its benefit for a suitable GBR.

## Introduction

In order to obtain effective bone regeneration using natural or synthetic fillers, a series of favourable conditions must occur that allow the body to perform the bone growth (15) as follows:

- presence of a blood clot with a high concentration of mesenchymal stem cells (MSC) capable of evolving in the osteoblast line and of endothelial cells forming a rich vascular network
- presence of vital bone tissue, from which osteogenic and angiogenic cells originate

through adequately prepared surrounding bone (cortical perforation)

- stabilization and maintenance of volume underneath the membrane
- protection of blood clot with a membrane, with the function of the stabilization of the clot, protecting growing vascular structures and blocking the migration of epithelial cells, which proliferate faster than bone cells.

In 1980 Nyman and Karring first introduced the concept of guided tissue regeneration (GTR) of

periodontal tissues, showing that the cells of soft tissue can grow faster than bone tissue (10). Thus, based on the results obtained, the migration of soft tissue cells above the implanted material must be stopped, thereby blocking migration within the porosity of the same material, thus promoting osseointegration rather than fibrointegration. The main characteristic of a membrane should be semi-permeability, i.e. the presence of porosity approximately 22 microns in diameter. Initially, a thin vascular network and a primary fibrous osteoid tissue -also called primary spongiosa- will begin to form within the clot. The latter is later mineralized thanks to osteoblasts that cover its surface, forming a new poorly calcified cortical bone.

The process stops when intertrabecular spaces narrow due to the formation of new bone tissue, until they reach the characteristic dimensions of Havers channel which, along with concentric lamellae, originate primary osteomas. All this occurs during the first 3-4 months, though actual bone remodelling requires more time, as it creates secondary spongiosa.

Research conducted by Hämmerle in 1996 (11) on human subjects confirmed what had previously been observed in animals, i.e. in the presence of large bone defects, regeneration can be limited to the more peripheral areas of the defect, while less activity is observed in the central area, where granules of biomaterial remain over time, though less frequently when tricalcium phosphate is used. The process of ossification always starts from the walls of the defect toward the center of the clot, along the newly formed vessels.

A number of studies clearly describe the regenerative ability of autologous bone compared with synthetic biomaterials, but unfortunately not without negative aspects. Indeed, collection from the donor site is very often painful for the patient; additionally, this results in longer surgical procedures and postoperative pain ; finally, the implanted material has a high degree of resorption (not a negligible factor).

The materials used for bone regeneration are grouped into: Autogenous bone, allogenic bone, xenogenic bone, alloplastic bone.

## Graft biomaterials

The alloplastic biomaterials available on the market represent an excellent alternative to autologous bone graft and are classified into two large groups: bioinert and bioactive, according to their interaction when they come into contact with the receiving site.

The main requirement of a synthetic biomaterial is to have a surface porosity that must promote colonization and development within its structure. These porosities must measure between 200/400 microns in diameter (Lynch et al., 2000; Bauer and Muschler, 2000). Synthetic biomaterials have been the subject of many studies, though their long term results have not always been considered. (1-2-3)

Today, osteoblastic cells or bone morphogenetic proteins (BMP obtained with in vitro cultures) can be added to a graft material (4-5) to enhance its osteoinductive and osteoconductive abilities and therefore reduce the time required for cells colonization. (6-7-8)

Among alloplastic biomaterials,  $\beta$ -tricalcium phosphate is the one that mostly displays a stable bond with bone neoformation; indeed, its characteristics have made it suitable for use in orthopedics since the early 1900s. In the presence of H<sub>2</sub>O it becomes instable, turning into hydroxyapatite, and this characteristic makes it suitable as an osteoconductive material (Coetree, 1980, De Leonardis and Pecora, 1999; 2000).

$\beta$ -TCP is characterized by a lower Ca/P ratio, which makes it more soluble than natural apatite. The Beta form is commonly obtained by mixing calcitis (CC) and dibasic calcium phosphate anhydrous (DCPA). The product obtained is rapidly cooled, and Alfa-TCP is obtained. Conversely, extended repeat baking at 800/950°C results in the beta form (9-12-13).

Multiple studies conducted on the TC and bone interaction have shown that histological examination at four months shows an initial bone neoformation in the intergranular spaces and in the surface porosity that helps guided bone formation. Indeed, the granules are reabsorbed by phagocytosis, releasing Ca/Mg and phos-

phates in the surrounding bone tissue, thereby activating alkaline phosphatase, a key ossification process. Between 6 and 18 months, fibroblasts begin invading the biomaterial, activating the extracellular dissolution process which ends with the calcification phase. If this should occur sooner, graft integration, rather than biodegradation, would happen. (5-6-7-8).

## R.T.R.

Synthetic, biocompatible and totally resorbable 99% pure tricalcium phosphate bone replacement, available in granules and in a cone shape, for regeneration in periodontal defects, implant, post-extraction bone defects and bone lesions following endodontic surgery.

The micro and macro-porous R.T.R. structure, with macropores measuring between 100 and 400  $\mu\text{m}$  and micropores measuring less than 10  $\mu\text{m}$ .

These morphological characteristics allow excellent osteogenic cell in-depth colonization and easy compacting.

Unlike hydroxyapatite, R.T.R. is progressively and totally reabsorbed, thereby releasing calcium and phosphate ions that participate actively in the formation of new bone tissue. Over a period of time between 6 and 9 months, which may vary according to the patient's physiological response, while stimulating bone regeneration, R.T.R. is progressively reabsorbed, leaving space for bone neoformation.

### Indications:

- Post-extraction sites
- Filling post-extraction sites to maintain the dimensions of alveolar bone
- Implant defects
- Sinus lift procedure
- Reconstruction of peri-implant defects
- Filling periodontal pockets with two or more walls
- Residual cavities after oral surgery (like cyst)
- Filling defects after apicectomy
- Alveolar filling following extraction of impacted teeth.

## Materials and methods

We conducted a multicenter study to evaluate the clinical application of R.T.R. ( $\beta$ -tricalcium phosphate).

This study examines the regeneration of bone defects with R.T.R. ( $\beta$ -tricalcium phosphate) in patients eligible for prosthetic implant rehabilitation. Patients were randomly selected, according to the following key criteria:

- aged between 20 and 60 years
- either male or female
- non-smokers
- in good general health
- having at least one crestal bone defect (no morphology and etiopathogenesis restrictions).

The cases treated were identified in the following clinical situations:

- Post-extraction sites
- Bone regeneration around implants placed in areas with bone loss or post-extraction.
- GBR (sinus lift or major bone defects).

In all cases, patients received antibiotic therapy with 1 gr every 8 h of Amoxicilline plus Clavulanic Acid (starting 24 hours before surgery up to day 5 post-surgery), repeated daily rinses with chlorhexidine and therapy with FANS (ibuprofen 800 mg/day in single dose), as necessary.

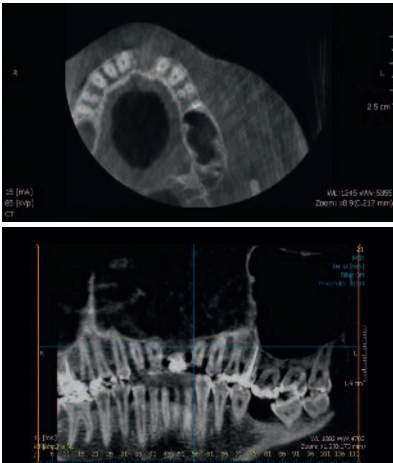
# Case Report no.1

**Patient:** Female

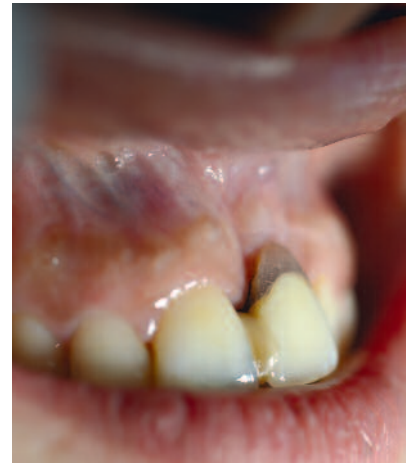**Age:** 30

**History:** odontogenic cyst in maxillary bone at 2.1.

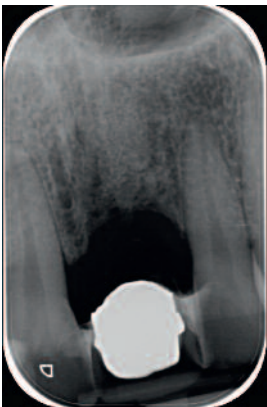
Cyst was removed in October 2013. Vertical guided regeneration with resorbable membrane and R.T.R. was performed. Implant placement: bone peak follow-up intraoral X-ray in consecutive months. 2<sup>nd</sup> surgery ISQ value: 61.



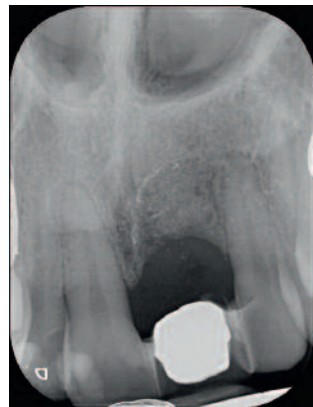**Fig. 1-4:** Different projections of radiographic C.T images show the large bone defect in site 2.1.



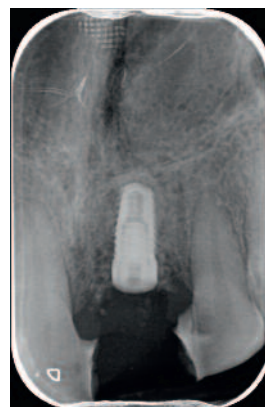
**Fig. 5:** Temporary prosthesis to cover the cosmetic defect.



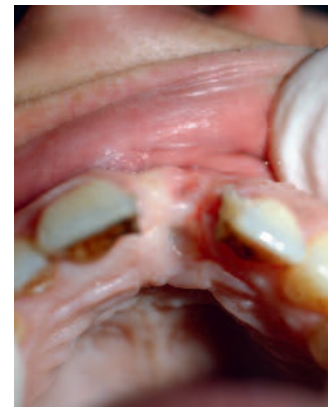**Fig. 6:** X-ray image before grafting.



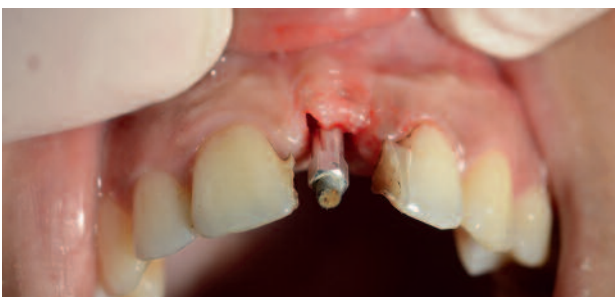**Fig. 7:** X-ray image after 5 months.



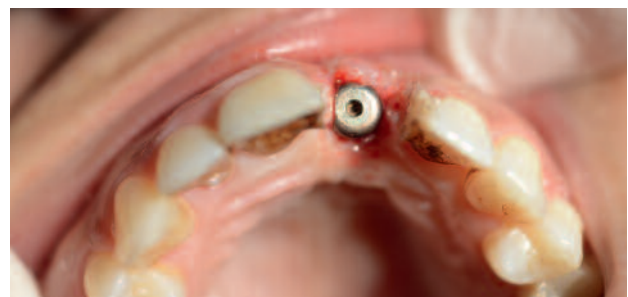**Fig. 8:** X-ray after insertion of the implant.



**Fig. 9:** The local objective examination and routine radiographic examination showed a good short-term healing.



**Fig. 10:** The ISQ test confirms a good stability of the implant.



**Fig. 11:** To obtain a good aesthetics of the final prosthesis is important to condition the soft tissue with the healing screws that favors the emergence profile.

# Case Report no.2

**Patient:** female

**Age:** 60

**History:** large cyst in upper maxillary bone extending from 2.2 to 1.1.

The cyst was removed and the cavity was filled with R.T.R. enhanced with PRGF (platelet-enriched plasma) and simultaneous placement of five implants was also performed.

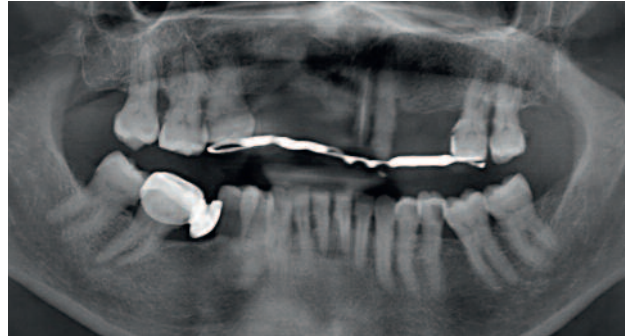
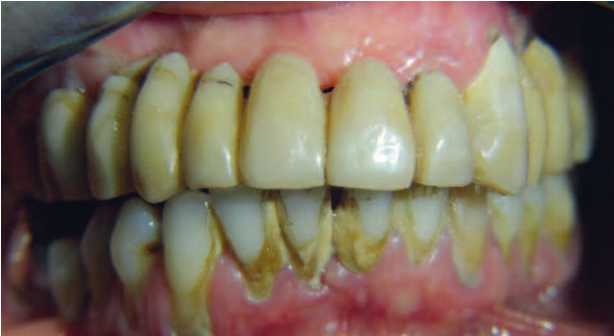

Fig. 12-13: Presence of large cysts of 2.1. The oral cavity examination shows a poor oral hygiene.

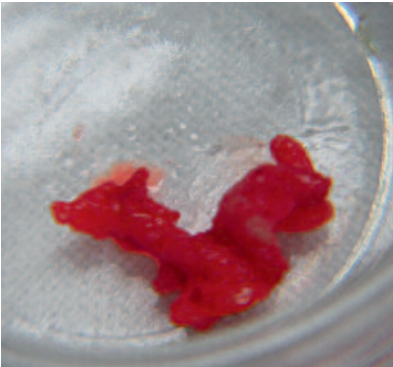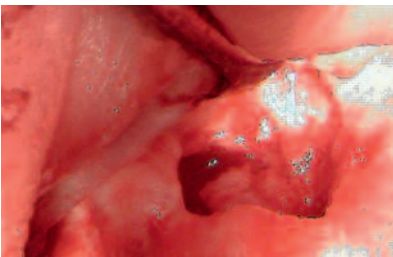


Fig. 14-15: Removal of the cyst; it is very important to remove all residual epithelial.

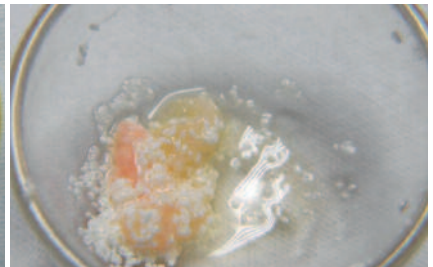
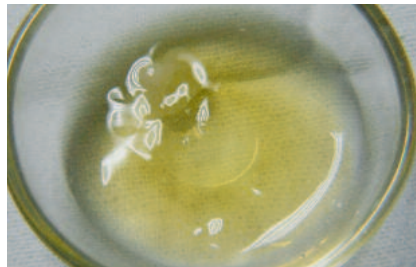
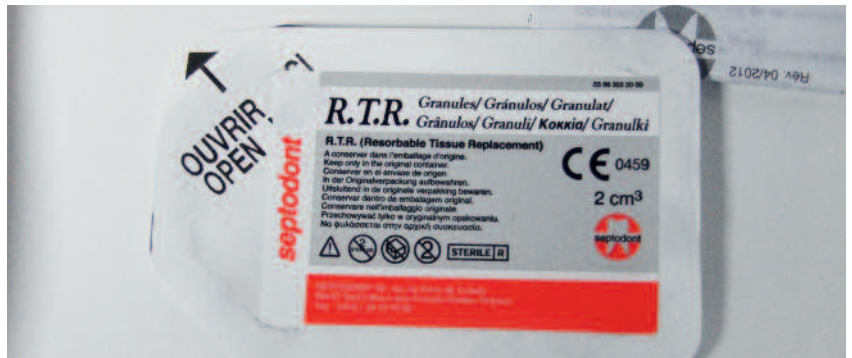

Fig. 16-17-18: Filling the bone cavity with granular R.T.R.

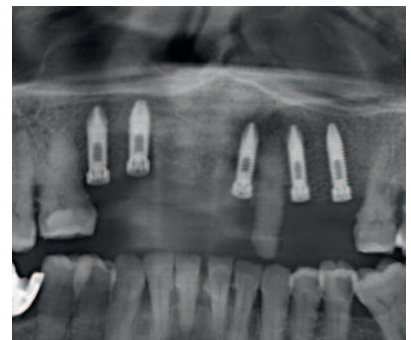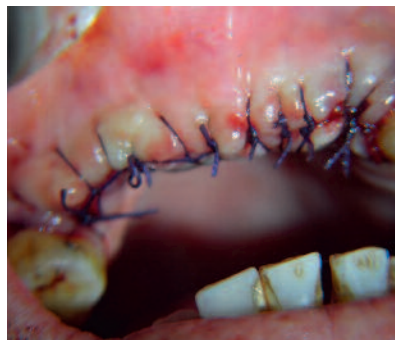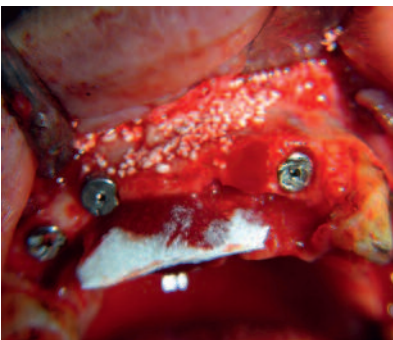


Fig. 19-20: During the same surgery were included five implants.

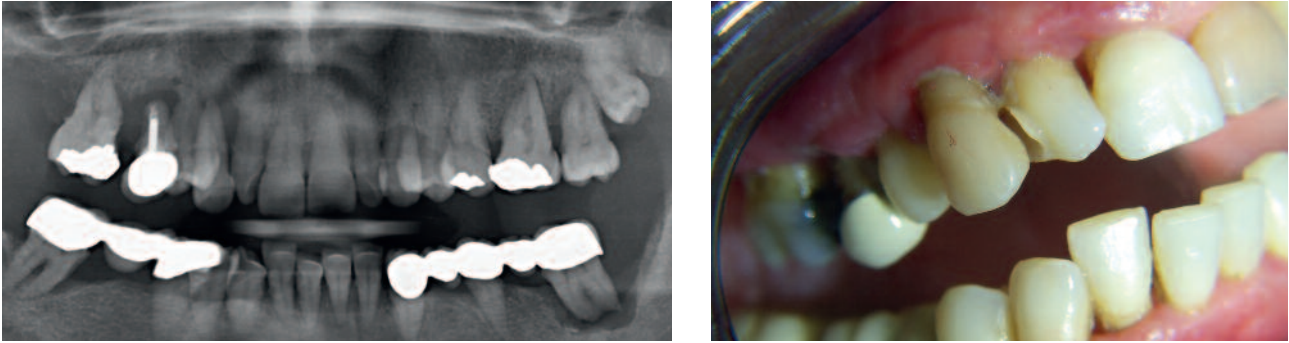
Fig. 21: X-ray control after five months.

# Case Report no.3

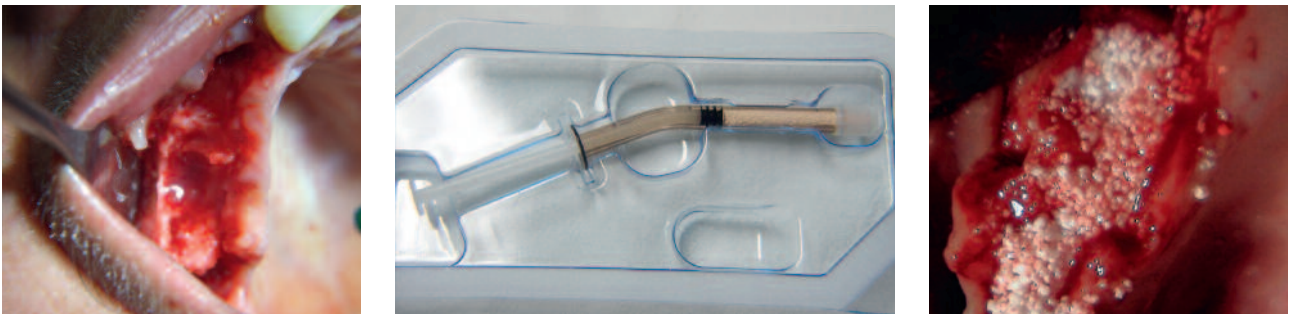**Patient:** female

**Age:** 50

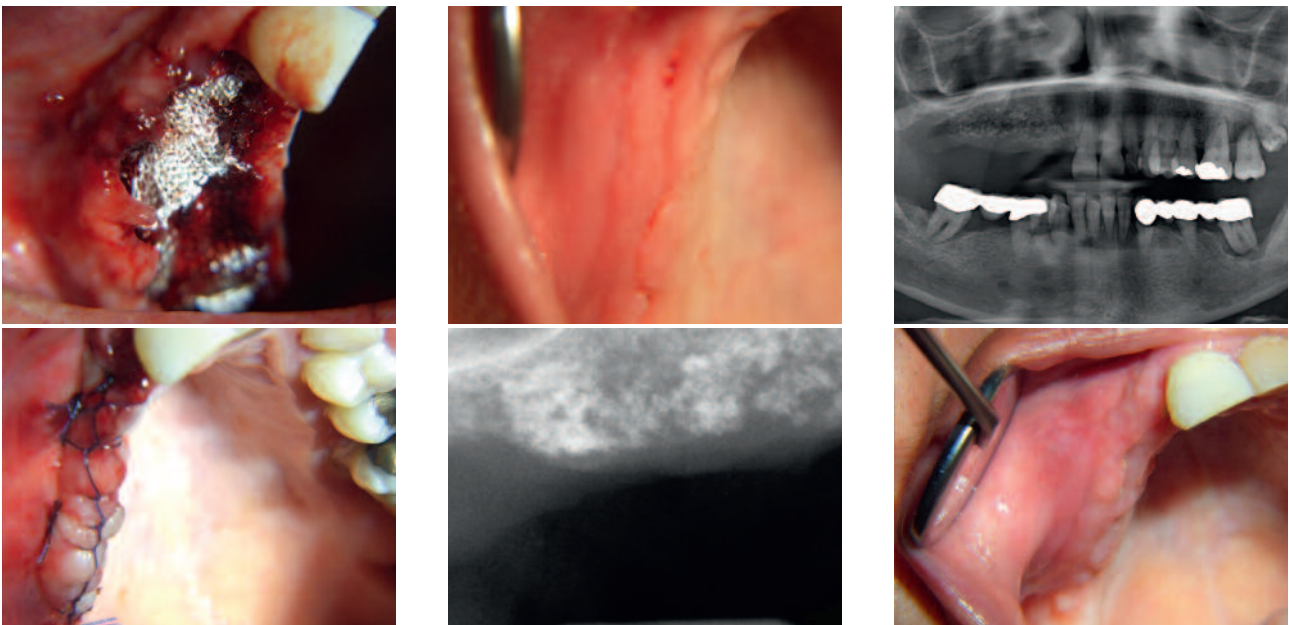
**History:** severe atrophy of the alveolar ridge, upper right jaw, affecting the area of 1.3, 1.4, 1.5, 1.6. These teeth were extracted and the alveolar ridge was reconstructed with R.T.R., covering biomaterial with Tabotamp (oxidized cellulose).



*Fig. 22-23:* Resorption of the alveolar process caused by periodontal disease. The local examination shows the class III mobility of the teeth.



*Fig. 24-25-26:* Resorption of the alveolar process caused by periodontal disease. The local examination shows the class III mobility of the teeth.



*Fig. 27-28:* Use of Tabotamp to cover the graft.

*Fig. 29-30:* The local examination after 10 days.

*Fig. 31-32:* The radiographic image after 4 months showed an increase in the vertical dimensions.

# Case Report no.4

**Patient:** female

**Age:** 30

**History:** root fracture of 1.6, previously treated with root canal treatment and large crown composite reconstruction. The roots were carefully extracted, and an implant was placed, using the interdicular septum bone and by performing an elevation of the maxillary sinus with osteotomes. The alveoli were filled with R.T.R. and covered with a collagen membrane.

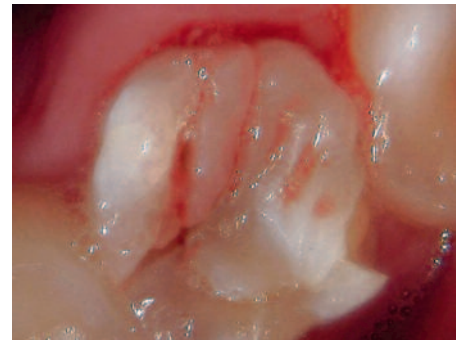
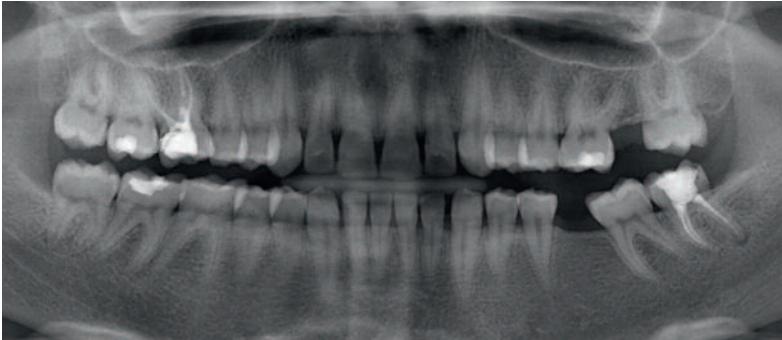


Fig. 33-34: Fracture of the first molar with the insertion of implant with post-extraction procedure.

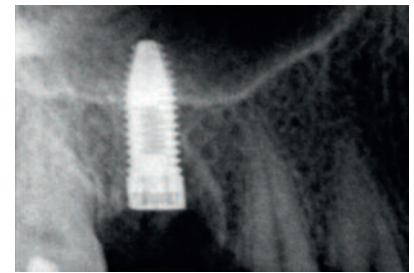
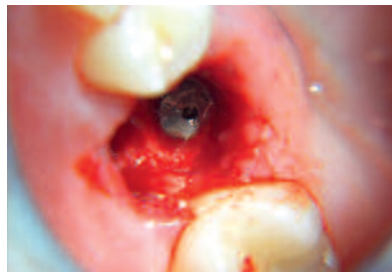
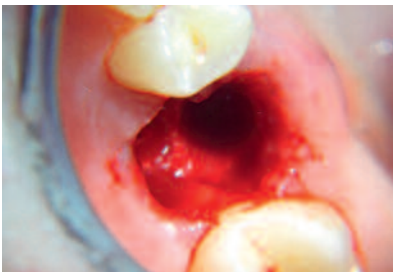
Fig. 35-36-37: Extraction was performed with piezosurgery technique to preserve the alveolar bone.

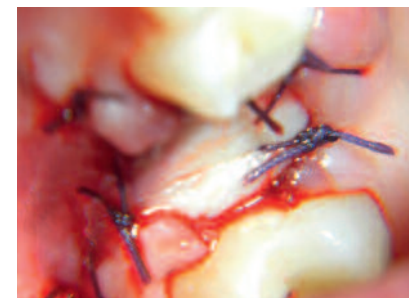
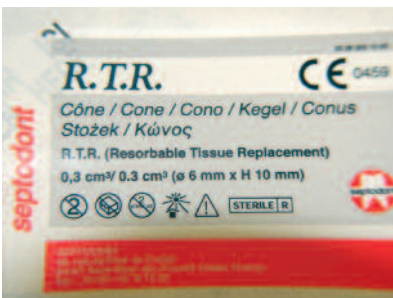

Fig. 38-39-40: The gap was filled using R.T.R.-size cone.

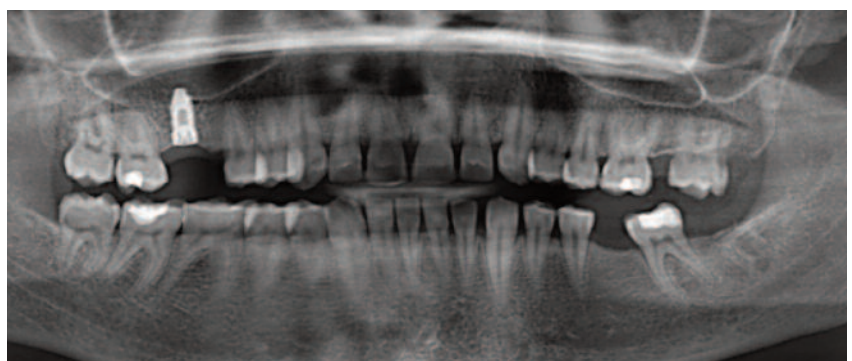
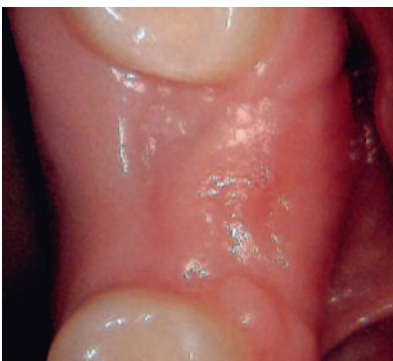

Fig. 41-42: The intraoral examination and radiographic examination after 4 months showed good integration of the implant.



# Case Report no.5

**Patient:** female

**Age:** 64

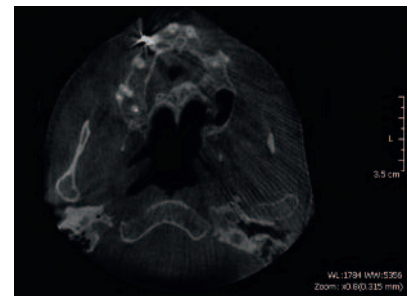
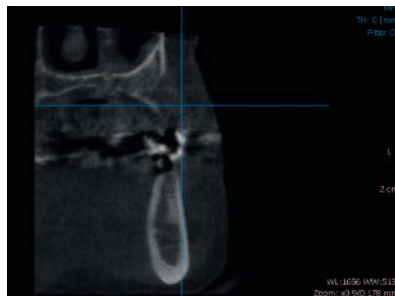
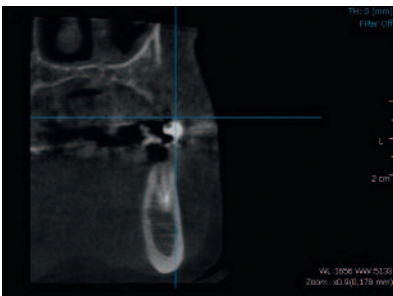
**History:** loss of 2.2 and 2.3 due to trauma.

CT revealed a significant resorption of buccal vestibular alveolar process.

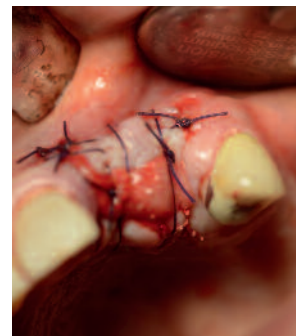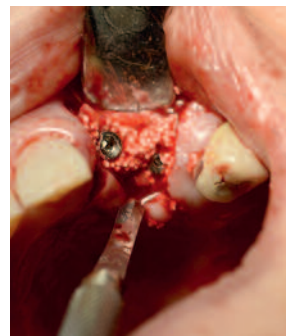
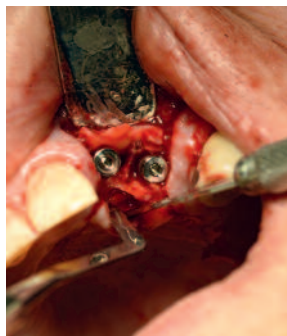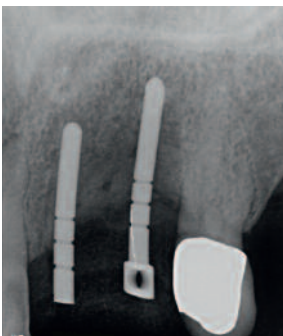Two implants were placed (measuring 3.3 mm in diameter and 13 mm long) and the gap was filled with R.T.R.

Re-opening was done after 5 months and evaluation of osseointegration with Osstel.

2.2 showed a value of 22-ISQ, and 2.3 –ISQ 64.

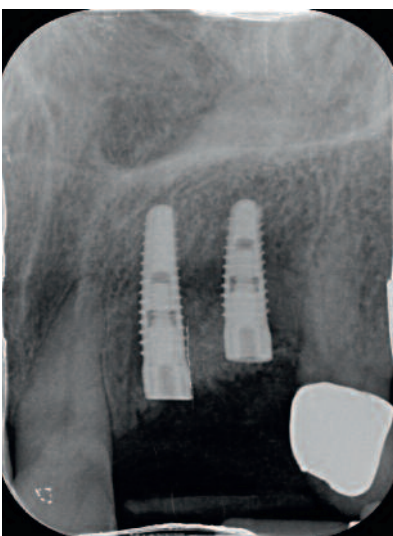

**Fig. 43-44-45:** Severe post-traumatic atrophy of the alveolar process in place 2.2- 2.3.

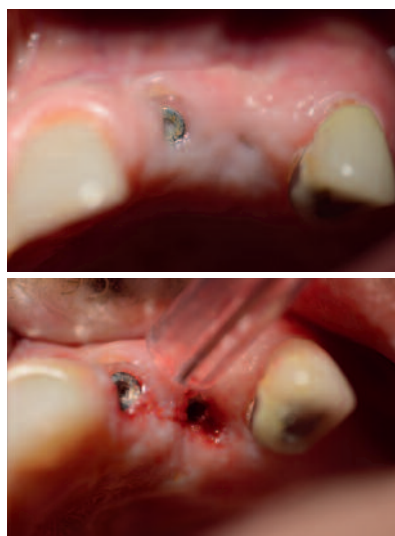

**Fig. 46-47:** Insertion of two implants with “split-crest” surgical technique.

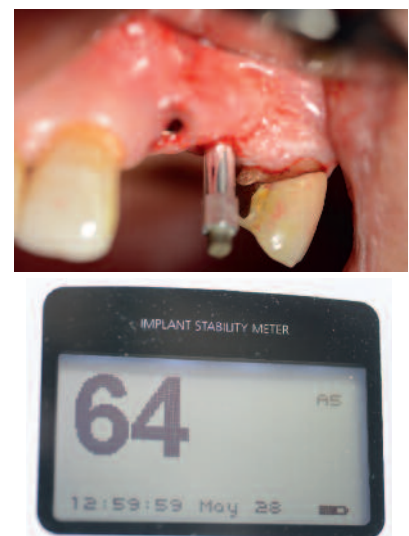
**Fig. 48-49:** The gap between the two margin bone was filled with phosphate-tricalcium R.T.R.



**Fig. 50:** X-ray control after 4 months showed a good bone density.



**Fig. 51-52:** The intraoral examination does appreciate a good recovery and an increase in bone volume.



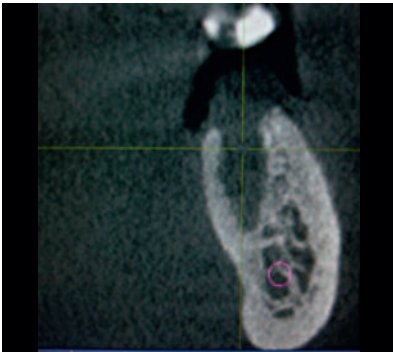
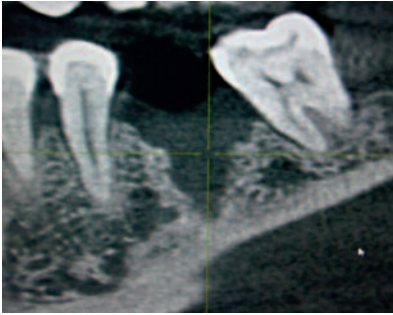
**Fig. 53-54:** The ISQ value confirms a good osseointegration.

# Case Report no.6

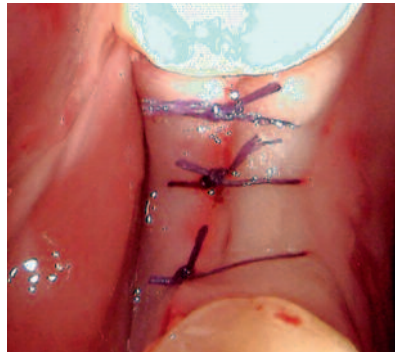
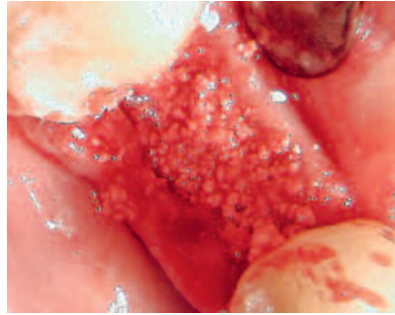
**Patient:** female

**Age:** 55

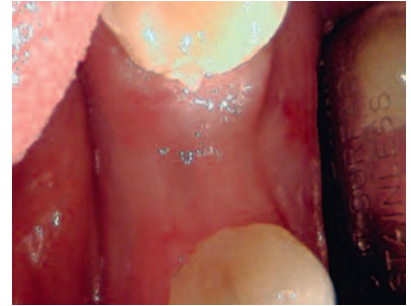
**History:** residual cyst at 3.6. To proceed to prosthetic molar rehabilitation with an implant, the cyst was extracted and the cavity was filled with R.T.R.; after a 4-month period for bone regeneration, the implant was placed.



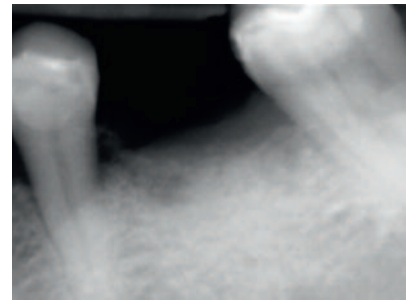
*Fig. 55-56:* The C.T. examination before surgery showed a residual cyst.



*Fig. 57-58:* After having removed the cyst, to speed up the healing time, the cavity has been filled with R.T.R. granules.



*Fig. 59:* Wound at 30 days.



*Fig. 60:* X-ray at 3 months.

## Conclusion

Based on the results obtained in the short term, the authors confirm the excellent properties of R.T.R., both in the first weeks of healing and in the following months, and they consider it an excellent alternative to autologous bone grafts. No inflammatory reactions or loss of bone volume evaluated clinically and radiographically

occurred in any of the cases examined. The most encouraging data came from the observation of the compactness and density of the bone neo-formation, which easily allowed the placement of implants with high ISQ values both during and after the placement of R.T.R. graft.



### Authors (left to right)

**Giuseppe Galvagna:** Dental practitioner, Catania, Italy

**Paolo Brunamonti Binello:** Consultant Professor, University of Genoa. Galliera Hospital, Genoa, Italy

**Massimo Galli:** Oral surgeon, dental practitioner, Pistoia, Italy

**Mauro Labanca:** Professor of Oral Surgery and Anatomy, Milan, Italy

## References

01. Labanca M., Leonida A., Rodella FL: Natural synthetic biomaterial in Dentistry: Science and ethics as criteria for their use. *Implantologia* 2008; 1:9-23
02. Ohgushi H, Caplan AI: Stem Cell Technology and Bioceramics: From Cell to Gene Engineering. *J Biomed Mater Res* 48(6): 913-927, 1999
03. Anselme K: Osteoblast adhesion on biomaterials. *Biomaterials* 2000 Apr; 21(7):667-81.
04. Toquet J, Roahanizadeh R, Guicheux J, Couillaud S, Passuti N, Daculsi G, Heymann D: Osteogenic Potential in vitro of human bone marrow cells cultured on macroporous biphasic
05. Maddox E, Zhan M, Mundy GR, Drohan WN, Burgess WH: Optimizing human demineralized bone matrix for clinical application. *Tissue Eng* 6(4): 441-448, 2000 calcium phosphate ceramic. *J Biomed Mater Res.* 1999 Jan; 44(1):98-108.
06. Gauthier O, Bouler JM, Aguado E, Pilet P, Daculsi G: Macroporous biphasic calcium phosphate ceramics: influence of macropore diameter and macroporosity percentage on bone ingrowth. *Biomaterials* 1998 Jan Feb;19(1-3):133-9.
07. Martinetti R, Belpassi A, Nataloni A, Biasini V, Martignani G: Idrossiapatite porosa sintetica per sostituzioni ossee: Caratterizzazione Chimico-Fisica. *Biomateriali: Atti del Congresso*; 51 55, Roma Enea, 1999
08. Martinetti R, Belpassi A et al.: Key Engineering Materials Vols. 192-195 (2001), 507-510 – Proceeding of the 13th Int. Symp. On Ceramics in Medicine, Bologna, Italy, 22-26 Nov.
09. Caplan AI: Mesenchymal stem cells. *J Orthop Res* 9: 641-650, 1999
10. Nyman S, Lindhe J, Karring T et Rylander H: New attachment following surgical treatment of human periodontal disease. *Journal of Clinical Periodontology* 9: 290-296, 1982; 39
11. Hämmerle CH, Brägger U, Bürgin W, Lang NP: The effect of subcrestal placement of the polished surface of ITI implants on marginal soft and hard tissues. *Clin Oral Implants Res.* 1996 Jun;7(2):111-9
12. Chin M: Distraction Osteogenesis in Maxillofacial Surgery. In Lynch SE, Genco RJ, Marx RE (eds). *Tissue Engineering – Application in Maxillofacial Surgery and Periodontics.* Illinois; Quintessence Publishing Co, Inc, 1999; 147
13. Arun K. Garg: Grafting Materials in Repair and Restoration. In Lynch SE, Genco RJ, Marx RE, (eds). *Tissue Engineering – Application in Maxillofacial Surgery and Periodontics.* Illinois; Quintessence Publishing Co, Inc, 1999; 83
14. Scipioni A, Bruschi GB, Calesini G: The edentulous ridge expansion technique: A five-year study. *Int J Periodont Rest Dent* 14: 451-459, 1994 Trans Tech Publications, Switzerland
15. Schenk RK and Buser D: Osseointegration: a reality. *Periodontology* 2000, Vol 17. 1998, 22.35
16. Bauer TW and Muschler GF: Bone graft materials. An overview of the basic science. *Clin Orthop Relat Res*, 2000 Feb;(371):10-27.